

UK Pathologist Rules 36-Year-Old Mom Most Likely Died From Pfizer COVID-19 mRNA Vaccine

Why proper autopsies of COVID vaccine victims are STILL not being done 3 years into global vaccination

By [Dr. William Makis](#)

Global Research, May 27, 2024

[COVID Intel](#)

Region: [Europe](#)

Theme: [Science and Medicine](#)

All Global Research articles can be read in 51 languages by activating the Translate Website button below the author's name (only available in desktop version).

To receive Global Research's Daily Newsletter (selected articles), [click here](#).

Click the share button above to email/forward this article to your friends and colleagues. Follow us on [Instagram](#) and [Twitter](#) and subscribe to our [Telegram Channel](#). Feel free to repost and share widely Global Research articles.

[Global Research Wants to Hear From You!](#)

May 2022 – Mother, 36, most likely died from Covid Pfizer vaccine 11 days after dose, inquest told – Pathologist said the mother-of-two may still be alive had she not had the Covid vaccine

Mother, 36, most likely died from Covid Pfizer vaccine 11 days after dose, inquest told

Pathologist said the mother-of-two may still be alive had she not had the Covid vaccine

Maryam Zakir-Hussain • Friday 06 May 2022 19:33 BST



Dawn Wooldridge with her husband, Ashley (HNP Newsdesk/Hyde News & Pictures Ltd)

A family listened in shock as a pathologist revealed his belief that a 36-year-old mother-of-two died as a result of having a [Pfizer Covid-19](#) vaccination.

A post-mortem examination on the body of Dawn Wooldridge had previously proved inconclusive.

But an inquest heard her unexpected death, which happened 11 days after the young mother's first Covid jab, was probably a result of the vaccination.

Ms Wooldridge was found dead in her home by her brother in June last year (2021), after she failed to collect her five-year-old son from school.

In a statement to the Berkshire coroner her husband, Ashley, said: "We met on holiday in Turkey and we have been married for seven years this year. We had our son nearly six years ago and our daughter just two years ago.

"My principal concern is that when they are old enough, I want to have enough of an

explanation about how their mum died. The only thing that happened when Dawn died was that she had her Covid jab before her death.”

The family, including her husband, her brother and his wife, and her step-parents attended the inquest in Reading.

They heard how the day of her death had been completely normal – she had dropped her son off at school in the morning, visited a friend for coffee and had spoken to her mother over the phone that afternoon.

The coroner said that Mrs Wooldridge’s medical records confirmed she received her first Covid-19 jab on 4 June.

Pathologist Dr Sukhvinder Ghataura told the coroner how her body had been healthy at the time of her death and how the toxicology report found no signs of alcohol or drugs in her system at the time.

The only points noted were inflammation of the heart, fluid in her lungs alongside a small clot on her lungs.

These, alongside menstrual irregularity and complaints of pain in her jaw and arm in the days after the [vaccine](#), the pathologist suggested, were linked to myocarditis (inflammation of the heart).

He told the coroner: “On the balance of probabilities, she had vaccine-related problems. There is nothing else for me to hang my hat on. It is the most likely reason, in my conclusion. It is more than likely Dawn died in response to the Covid jab.”

Ms Wooldridge’s brother, Stuart Lynch, asked the pathologist: “Do you think she would still be alive if she hadn’t had the vaccine?”

Dr Ghataura responded: “It’s a difficult question but I would say yes. I wish to pass on my condolences to Dawn’s family.”

Concluding the inquest, assistant coroner Alison McCormick said: “Dawn was a 36-year-old married lady. Her husband Ashley and her members of her family are here today as a testament to the woman she was.

“She lived in Twyford, near Wokingham, Berkshire, and was a full-time mum. She had no significant medical history and was not on any medication when she died. She had her first Pfizer vaccine on 4 June 2021, and evidence after that shows her periods became irregular.

“She also reported pains in her arm and her jaw. 15 June 2021 was a normal day for her. There is no evidence she was ill that day. She walked her son to school in the morning and went to get coffee with a friend. That afternoon she had a 15-20 minute phone call with her mum.

“She didn’t however pick her son up from school. Her brother went to the house where he saw her face down, collapsed on the floor. She had been on the toilet prior to her collapse.

“With the help of a local builder he gained access to the house, and a defibrillator was used. Police and paramedics attended quickly, but despite their efforts no life-saving opportunities

were available and she passed away at her home address on that day.

“Subsequent to her death, a toxicology and post-mortem examination were undertaken and initially, Dr Ghataura said he was unable to provide a cause for Dawn’s death, stating the post-mortem findings were “unascertained”.

“Today I heard from Dr Ghataura and during the course of the evidence he expressed a change of view that in the balance of probabilities, it is more likely than not she died from acute myocarditis due to her recent Covid-19 immunisation.

“I give the narrative conclusion that her death was caused by acute myocarditis, due to recent Covid-19 immunisation. Ashley, you will have something to say to your children to explain why their mother died so tragically.”

The Medicine and Healthcare products Regulatory Agency (MHRA) confirmed on 9 September 2021 that Covid-19 vaccines made by Pfizer and AstraZeneca [can be used as safe and effective booster doses](#), as well as the Moderna vaccine.

Furthermore, a [major study of vaccine side-effects in the US published in March 2022](#) found no link between two Covid jabs and the number of deaths recorded after vaccination.

My Take...

Kudos to this UK pathologist for having the guts to determine the proper cause of death in this 36 year old mom.

I have also seen US, New Zealand, German, South Korean and Japanese pathologists do the same. It takes courage.

There has not been 1 Canadian pathologist (or an Australian pathologist) with the guts to make a formal determination that a COVID-19 Vaccine caused a sudden death (that’s why I say that Canadian doctors who pushed the jabs and medical leaders are the worst, most incompetent doctors in the world).

Proper Autopsies are not being done...

This autopsy itself was far from ideal or “proper”. This is what is called a “diagnosis of exclusion”. When you’ve ruled out everything else and you’ve left with the most obvious answer.

But we have a way of determining if the COVID-19 Vaccine caused a death.

It’s called immunohistochemistry. You can do staining of tissues for COVID-19 nucleocapsid protein and spike protein.

Here is an example of such a staining done by researchers in Singapore:

[2021 June \(Denise Goh et al\)](#) – Residual SARS-CoV-2 viral antigens detected in GI and hepatic tissues from five recovered patients with COVID-19

- “Using conventional immunohistochemistry, we detected SARS-CoV-2 nucleocapsid protein (NP) in the colon, appendix, ileum, haemorrhoid, liver, gallbladder and lymph nodes (figure 1A-K) from five patients who recovered

from COVID-19, ranging from 9 to 180 days after testing negative for SARS-CoV-2”

- “all the tissues showed the presence of the viral antigen, suggesting widespread multiorgan involvement of the viral infection.”
- “Interestingly, for the colon, the viral antigen was only present in normal colonic crypts and polyps but not in the neoplastic tissues (figure 1Q). Similar negative staining in the hepatocellular carcinoma tumour region was also observed”

Translation: They were able to do staining for SARS-CoV-2 nucleocapsid protein and spike protein in patients who recovered from COVID-19 Infection. Interestingly, viral antigens were not found in tumor tissue but were found in many normal tissues.

Residual SARS-CoV-2 viral antigens detected in GI and hepatic tissues from five recovered patients with COVID-19

We read with great interest the article published by Zuo *et al*, which highlighted the presence of SARS-CoV-2 RNA in stool samples during active and convalescence phases of COVID-19 infection.¹ However, no study has reported the presence of viral antigens within GI and hepatic organs during the convalescent phase.

Using conventional immunohistochemistry, we detected SARS-CoV-2 nucleocapsid protein (NP) in the colon, appendix, ileum, haemorrhoid, liver, gallbladder and lymph nodes (figure 1A–K) from five patients who recovered from COVID-19, ranging from 9 to 180 days after testing negative for SARS-CoV-2 (online supplemental table 1). Notably, when multiple tissues were obtained from one patient (patients 1 and 4), all the tissues showed the presence of the viral antigen, suggesting widespread multiorgan involvement of the viral infection. Interestingly, for the colon, the viral antigen was only present in normal colonic crypts and polyps but not in the neoplastic tissues (figure 1Q). Similar negative staining in the hepatocellular carcinoma tumour region was also observed (figure 1R) albeit the positive staining in some of the scattered immune cells (figure 1D). Validating our findings, we detected SARS-CoV-2 spike protein (figure 1L–P) and RNA (figure 2B–F) in the above-mentioned tissues using conventional immunohistochemistry and RNAscope, respectively. However, we were unable to detect viral RNA in some patients' tissues (online supplemental table 1), possibly because of higher RNA degradation rate as compared with protein and other patient-dependent factors such as disease severity, time since recovery and basal metabolic rate.

In addition, multiplex immunohistochemistry and RNAscope staining showed that some SARS-CoV-2-positive cells colocalised with ACE2 receptor and CD68 in the colon and liver (figure 2A,B). These cells were likely of monocyte lineage and liver-resident sinusoidal Kupffer cells, which therefore confirmed our

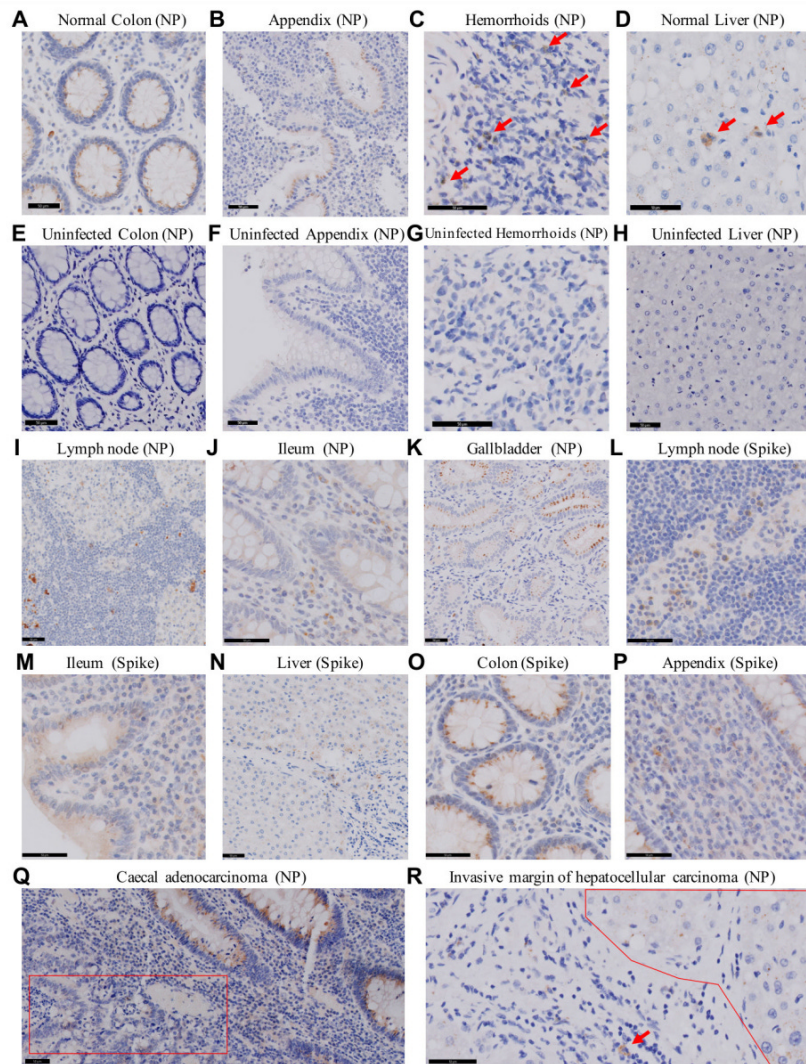
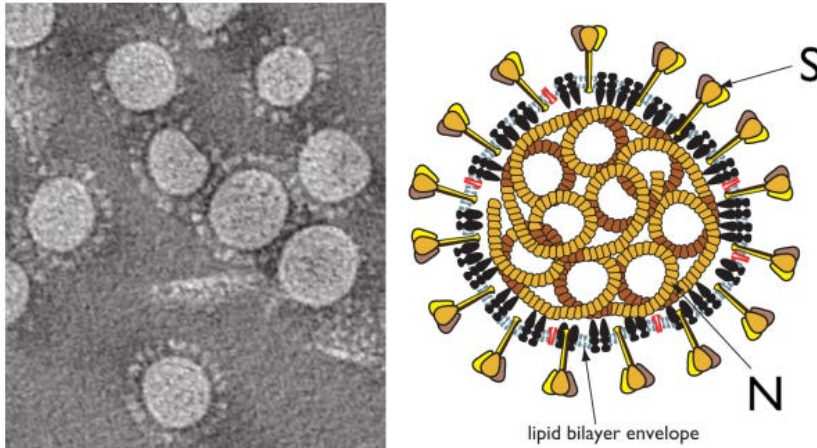


Figure 1 Immunohistochemical staining of the SARS-CoV-2 nucleocapsid and spike proteins in intestinal and hepatic tissues. (A and B) Positive SARS-CoV-2 nucleocapsid protein (NP) staining in colonic crypts (A) and appendix (B), both with a granular supranuclear cytoplasmic pattern. (C) positive SARS-CoV-2 NP staining in scattered immune cells in haemorrhoid tissue (red arrows). (D) positive SARS-CoV-2 NP staining in sinusoidal Kupffer cells in the liver (red arrows). (E–H) Representative images of negative SARS-CoV-2 NP staining in colon, appendix, haemorrhoid and liver tissues taken from individuals with no history of COVID-19. (I) Positive SARS-CoV-2 NP staining in scattered immune cells within the lymph node. (J and K) Positive SARS-CoV-2 NP staining in ileum (J) and gallbladder (K), both with a granular supranuclear cytoplasmic pattern. (L) Positive SARS-CoV-2 spike protein staining in scattered immune cells within the lymph node. (M–P) Positive SARS-CoV-2 spike protein staining in the ileum (M), liver (N), colon (O) and appendix (P). (Q) Positive SARS-CoV-2 NP staining in normal colonic crypts (top right) but negative staining in the adjacent neoplastic glands (bottom left, red box). (R) Scattered SARS-CoV-2 NP-positive immune cells were seen along the invasive margin of hepatocellular carcinoma, as indicated by the red arrows. Hepatocellular carcinoma tumour region, as demarcated by the red box, was negative for SARS-CoV-2 NP. (A–R) Scale bar: 50 µm.

[2022 Article](#) – Dr. Michael Palmer and Dr. Sucharit Bhakdi – Vascular and organ damage induced by mRNA vaccines: irrefutable proof of causality

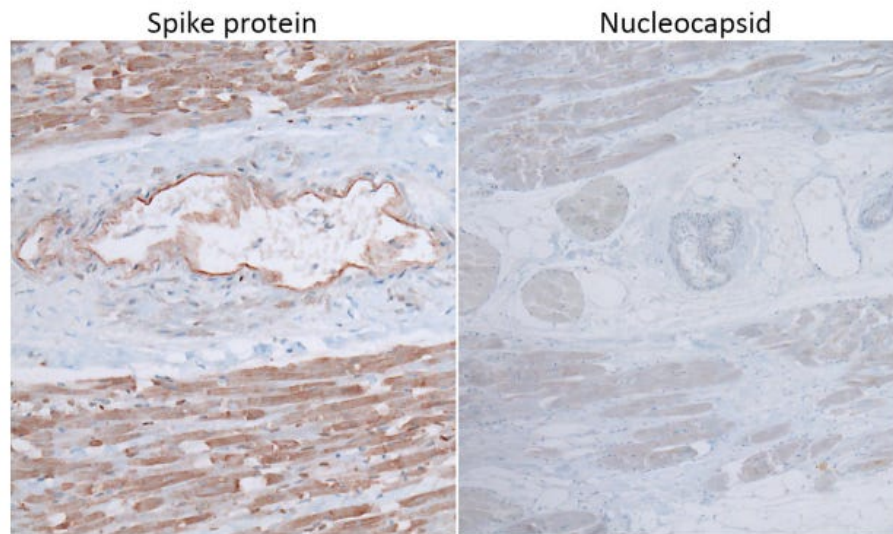
“Prof. Burkhardt is a very experienced pathologist from Reutlingen, Germany. With the help of his colleague Prof. Walter Lang, he has studied numerous cases of death which occurred within days to several months after vaccination. In each of these cases, the cause of death had been certified as “natural” or “unknown.” Burkhardt became involved only because the bereaved families doubted these verdicts and sought a second opinion. It is remarkable, therefore, that Burkhardt found not just a few but the majority of these deaths to be due to vaccination.”

5 Coronavirus particles contain two prominent proteins: spike (S) and nucleocapsid (N)



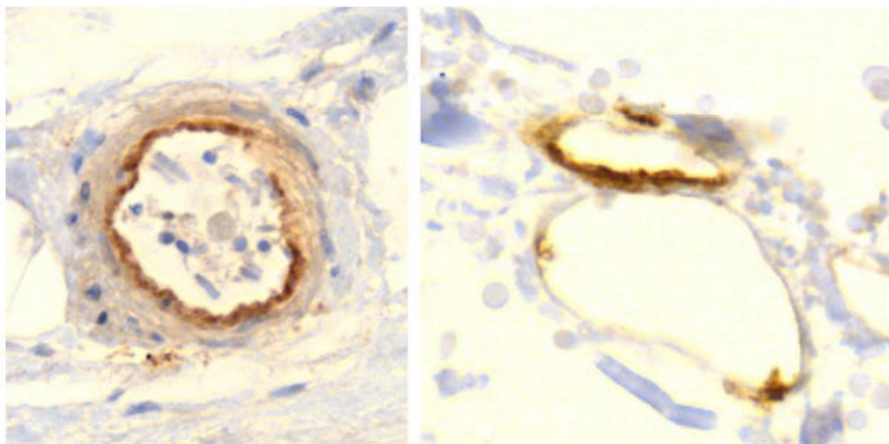
To distinguish between infection and injection, we can again use immunohistochemistry, but this time apply it to another SARS-CoV-2 protein—namely, the nucleocapsid, which is found inside the virus particle, where it enwraps and protects the RNA genome. The rationale of this experiment is simple: cells infected with the virus will express all viral proteins, including the spike and the nucleocapsid. In contrast, the mRNA-based COVID vaccines (as well as the adenovirus vector-based ones produced by AstraZeneca and Janssen) will induce expression only of spike.

7 Injected persons express *only* the spike protein, which implicates the vaccine



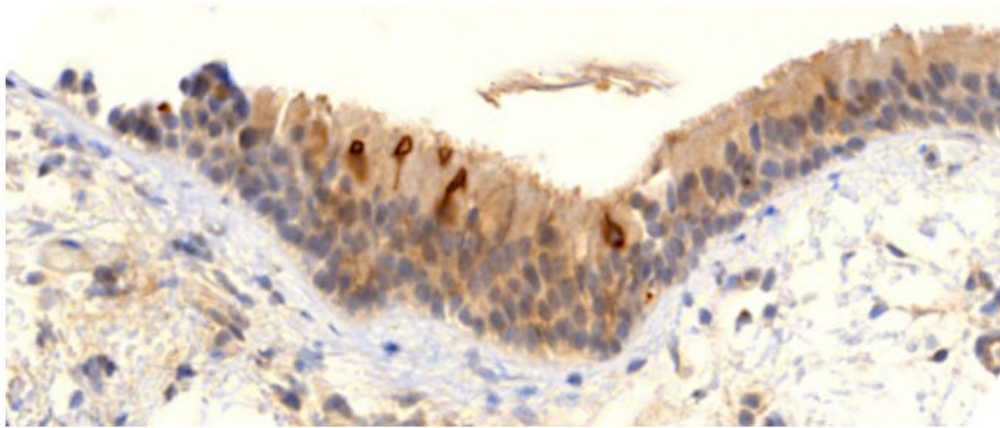
Here, we see immunohistochemistry applied to heart muscle tissue from an injected person. Staining for the presence of spike protein causes strong brown pigment deposition. In contrast, only very weak, non-specific staining is observed with the antibody that recognizes the nucleocapsid protein. The absence of nucleocapsid indicates that the expression of the spike protein must be attributed to the vaccine rather than an infection with SARS-CoV-2.

8 Expression of spike protein within the walls of small blood vessels



We see spike protein expression in arterioles (small arteries; left) as well as in venules (small veins) and capillaries (right). Expression is most prominent in the innermost cell layer, the *endothelium*. This makes the endothelial cells “sitting ducks” for an attack by the immune system.

13 Vaccine-induced expression of spike protein in a bronchial biopsy nine months after vaccination



The slide shows a sample of bronchial mucous membrane, from a patient who is alive but has suffered respiratory symptoms ever since being vaccinated. We see several cells in the uppermost cell layer that strongly express spike protein—and this even nine months after his most recent vaccine injection! While this is indeed the most extreme case of long-lasting expression, there is evidence both from Burkhardt's autopsies and from published studies on blood samples [8] or lymph node biopsies [9] to indicate that expression does last several months.

[2022 Oct \(Michael Morz\)](#) – A Case Report: Multifocal Necrotizing Encephalitis and Myocarditis after BNT162b2 mRNA Vaccination against COVID-19

“Case of a 76-year-old man with Parkinson’s disease (PD) who died three weeks after receiving his third COVID-19 vaccination. The patient was first vaccinated in May 2021 with the ChAdOx1 nCov-19 vector vaccine, followed by two doses of the BNT162b2 mRNA vaccine in July and December 2021. The family of the deceased requested an autopsy due to ambiguous clinical signs before death.”

“Immunohistochemistry for SARS-CoV-2 antigens (spike and nucleocapsid proteins) was performed. Surprisingly, only spike protein but no nucleocapsid protein could be detected within the foci of inflammation in both the brain and the heart, particularly in the endothelial cells of small blood vessels. Since no nucleocapsid protein could be detected, the presence of spike protein must be ascribed to vaccination rather than to viral infection.”

Brain

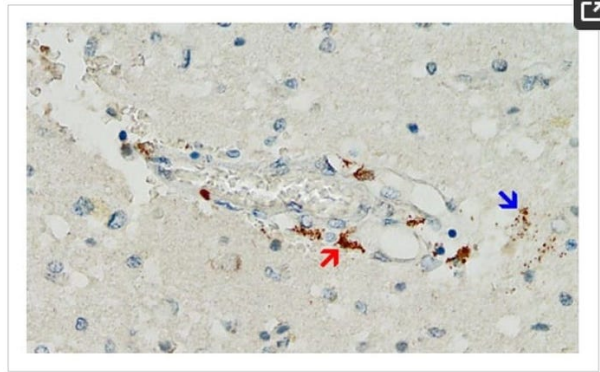


Figure 9. Frontal brain. **Positive reaction for SARS-CoV-2 spike protein.** Cross section through a capillary vessel (same vessel as shown in Figure 11, serial sections of 5 to 20 μm). Immunohistochemical reaction for SARS-CoV-2 spike subunit 1 detectable as brown granules in capillary endothelial cells (red arrow) and individual glial cells (blue arrow). Magnification: 200 \times .

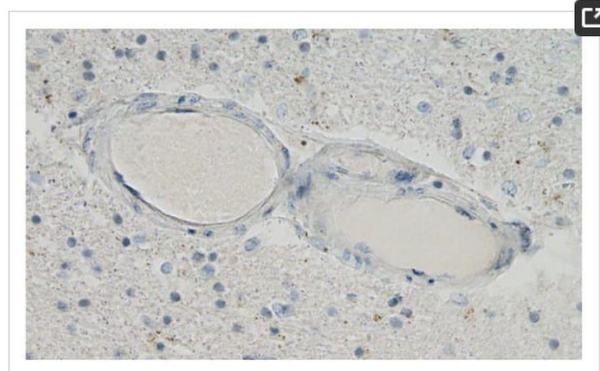


Figure 11. Frontal brain. **Negative immunohistochemical reaction for SARS-CoV-2 nucleocapsid protein.** Cross section through a capillary vessel (same vessel as shown in Figure 9, serial sections of 5 to 20 μm). Magnification: 200 \times .

A Case Report: Multifocal Necrotizing Encephalitis and Myocarditis after BNT162b2 mRNA Vaccination against COVID-19

by Michael Mörz 

Institute of Pathology 'Georg Schmorl', The Municipal Hospital Dresden-Friedrichstadt, Friedrichstrasse 41, 01067 Dresden, Germany

Vaccines **2022**, *10*(10), 1651; <https://doi.org/10.3390/vaccines10101651>

Submission received: 31 August 2022 / Revised: 25 September 2022 / Accepted: 27 September 2022 / Published: 1 October 2022

Heart

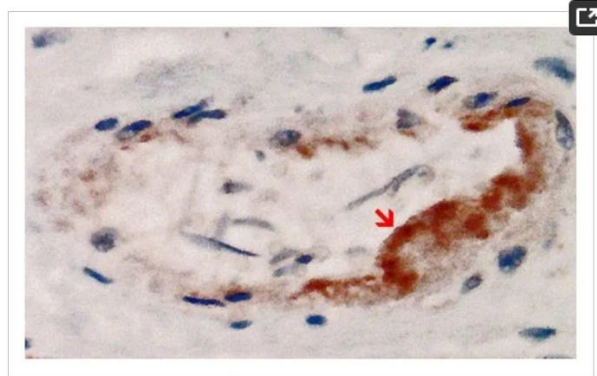


Figure 13. Heart left ventricle. Positive reaction for SARS-CoV-2 spike protein. Cross section through a capillary vessel (same vessel as shown in Figure 14, serial sections of 5 to 20 μm). Immunohistochemical demonstration of SARS-CoV-2 spike subunit 1 as brown granules. Note the abundant presence of spike protein in capillary endothelial cells (red arrow) associated with prominent endothelial swelling and the presence of a few mononuclear inflammatory cells. Magnification: 400 \times .

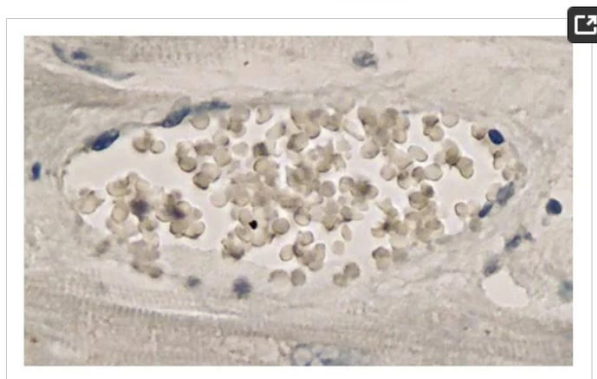


Figure 14. Heart left ventricle. Negative immunohistochemical reaction for SARS-CoV-2 nucleocapsid protein. Cross section through a capillary vessel (same vessel as shown in Figure 13, serial sections of 5 to 20 μm). Magnification: 400 \times .

A Case Report: Multifocal Necrotizing Encephalitis and Myocarditis after BNT162b2 mRNA Vaccination against COVID-19

by Michael Mörz

Institute of Pathology 'Georg Schmorl', The Municipal Hospital Dresden-Friedrichstadt, Friedrichstrasse 41, 01067 Dresden, Germany

Vaccines **2022**, *10*(10), 1651; <https://doi.org/10.3390/vaccines10101651>

Submission received: 31 August 2022 / Revised: 25 September 2022 / Accepted: 27 September 2022 / Published: 1 October 2022

Conclusion

Every sudden or unexplained death should have an autopsy done with immunohistochemistry for SARS-CoV-2 antigens (spike and nucleocapsid proteins) performed.

It's not expensive or time consuming and we would have answers about 1000s of these unexplained deaths and their relationship to either COVID-19 mRNA Vaccines or Long COVID.

But immunohistochemistry for SARS-CoV-2 antigens is not being done in United States, Canada, Australia, New Zealand, or UK. WHY?

Because the medical authorities know that most sudden and unexplained deaths are caused

by the COVID-19 mRNA Vaccines, not Long COVID. And they have been tasked by Big Pharma to protect a \$200+ billion mRNA Industry at all costs.

That's why mRNA factories continue to be built around the world. They have no intention of stopping, no matter how many people die.

It is the medical leadership in these countries, bought off by big pharma, that is blocking proper autopsies with immunohistochemistry for SARS-CoV-2 antigens from being done routinely by pathologists.

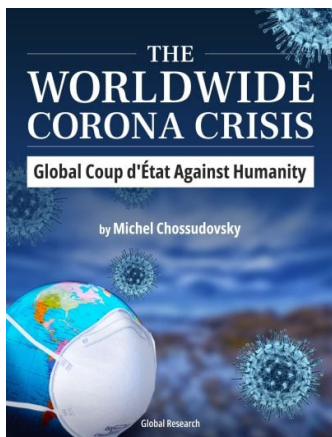
Same problem when it comes to cancer tissue pathology, immunohistochemistry for SARS-CoV-2 antigens is not being done, to avoid linking COVID-19 mRNA Vaccines to TURBO CANCER.

*

Note to readers: Please click the share button above. Follow us on Instagram and Twitter and subscribe to our Telegram Channel. Feel free to repost and share widely Global Research articles.

Dr. William Makis is a Canadian physician with expertise in Radiology, Oncology and Immunology. Governor General's Medal, University of Toronto Scholar. Author of 100+ peer-reviewed medical publications.

Featured image is from NaturalNews.com



The Worldwide Corona Crisis, Global Coup d'Etat Against Humanity

by Michel Chossudovsky

Michel Chossudovsky reviews in detail how this insidious project “destroys people’s lives”. He provides a comprehensive analysis of everything you need to know about the “pandemic” — from the medical dimensions to the economic and social repercussions, political underpinnings, and mental and psychological impacts.

“My objective as an author is to inform people worldwide and refute the official narrative which has been used as a justification to destabilize the economic and social fabric of entire countries, followed by the imposition of the “deadly” COVID-19 “vaccine”. This crisis affects humanity in its entirety: almost 8 billion people. We stand in solidarity with our fellow

human beings and our children worldwide. Truth is a powerful instrument."

Reviews

This is an in-depth resource of great interest if it is the wider perspective you are motivated to understand a little better, the author is very knowledgeable about geopolitics and this comes out in the way Covid is contextualized. —Dr. Mike Yeadon

In this war against humanity in which we find ourselves, in this singular, irregular and massive assault against liberty and the goodness of people, Chossudovsky's book is a rock upon which to sustain our fight. -Dr. Emanuel Garcia

In fifteen concise science-based chapters, Michel traces the false covid pandemic, explaining how a PCR test, producing up to 97% proven false positives, combined with a relentless 24/7 fear campaign, was able to create a worldwide panic-laden "plandemic"; that this plandemic would never have been possible without the infamous DNA-modifying Polymerase Chain Reaction test – which to this day is being pushed on a majority of innocent people who have no clue. His conclusions are evidenced by renown scientists. —Peter Koenig

Professor Chossudovsky exposes the truth that "there is no causal relationship between the virus and economic variables." In other words, it was not COVID-19 but, rather, the deliberate implementation of the illogical, scientifically baseless lockdowns that caused the shutdown of the global economy. -David Skripac

A reading of Chossudovsky's book provides a comprehensive lesson in how there is a global coup d'état under way called "The Great Reset" that if not resisted and defeated by freedom loving people everywhere will result in a dystopian future not yet imagined. Pass on this free gift from Professor Chossudovsky before it's too late. You will not find so much valuable information and analysis in one place. -Edward Curtin

ISBN: 978-0-9879389-3-0, Year: 2022, PDF Ebook, Pages: 164, 15 Chapters

Price: ~~\$11.50~~ FREE COPY! [Click here \(docsend\) and download.](#)

[You may also access the online version of the e-Book by clicking here.](#)

We encourage you to support the eBook project by making a donation through Global Research's [DonorBox "Worldwide Corona Crisis" Campaign Page.](#)

The original source of this article is [COVID Intel](#)
Copyright © [Dr. William Makis](#), [COVID Intel](#), 2024

[Comment on Global Research Articles on our Facebook page](#)

[Become a Member of Global Research](#)

Disclaimer: The contents of this article are of sole responsibility of the author(s). The Centre for Research on Globalization will not be responsible for any inaccurate or incorrect statement in this article. The Centre of Research on Globalization grants permission to cross-post Global Research articles on community internet sites as long the source and copyright are acknowledged together with a hyperlink to the original Global Research article. For publication of Global Research articles in print or other forms including commercial internet sites, contact: publications@globalresearch.ca

www.globalresearch.ca contains copyrighted material the use of which has not always been specifically authorized by the copyright owner. We are making such material available to our readers under the provisions of "fair use" in an effort to advance a better understanding of political, economic and social issues. The material on this site is distributed without profit to those who have expressed a prior interest in receiving it for research and educational purposes. If you wish to use copyrighted material for purposes other than "fair use" you must request permission from the copyright owner.

For media inquiries: publications@globalresearch.ca